



PATIENT

Carlos Romero

SPECIES

Canine

BREED

Dachshund

SEX

Male Intact

AGE

5 months

WEIGHT

9lbs

INTERPRETED BY

Maggie Machen Lamy,
DVM, DACVIM
(Cardiology)

IMAGING PERFORMED BY

Cole England, DVM

HOSPITAL NAME

Blue Cross Animal
Clinic

REFERRING VET

Dr. Andrews

INVOICE

47096

DATE

3/4/26

PRESENTING CLINICAL SIGNS

History: Coughing for 2 months. CXR showed slight pleural effusion and possible right-sided cardiomegaly (not available). No murmur. On Doxycycline for potential kennel cough.

RADIOGRAPHIC FINDINGS *NOTE: Images submitted for supplemental cardiac information only.

Normal cardiac silhouette. No obvious evidence of CHF.

ECHOCARDIOGRAM FINDINGS

2D, m-mode, color flow and doppler imaging is available. Mild MV thickening with no prolapse into the left atrial lumen. No obvious mitral regurgitation with a normal left atrial dimension. Normal LV diameter with adequate myocardial function. The tricuspid valve appears normal with no tricuspid regurgitation. Normal right atrial and ventricular diameter and morphology indicating no overt evidence of pulmonary arterial hypertension. The pulmonic and aortic valves are normal in morphology and mobility. Normal pulmonic and aortic outflow velocities with laminar flow. No obvious aortic and trace pulmonic insufficiency. No pericardial or pleural effusion noted. No obvious cardiac masses.

CARDIAC CHART

CANINE CARDIAC PARAMETERS	MR VMAX (m/s)	TR VMAX (m/s)	LA/AO (Boon method)	LA/AO (Heart Base; Swe)	FS (%)	EF (%)	EPSS (cm)
NORMAL PARAMETER	4.5-5.5	<2.7	1.3	<1.6	28-40	40-100	<0.6
PATIENT	NA	NA	NM	1.2	40	76	NM
CANINE CARDIAC PARAMETERS	HR (BPM)	AV VMAX (m/s)	PV MAX (m/s)	BODY WEIGHT (kg)	LA 2D short axis Base view (cm)	LVIDd Avg; 2D and m-mode short axis (cm)	LVIDs Avg; 2D and m-mode short axis (cm)
NORMAL PARAMETER	50-100	0.7-1.7	0.7-1.6	BELOW	BELOW	BELOW	BELOW
PATIENT	NM	1.0	0.9	4.1	1.2	2.1	1.3
*Normal chamber parameters expressed as a mean value (SD)				3	1.27 (5.3)	2.46 (2.46)	1.36 (5.5)
BODY WEIGHT DEPENDENT PARAMETERS				5	1.40 (4.5)	2.74 (5.2)	1.60 (4.7)
*Note: All measurements based upon multi-modal images and methods. An average value is reported.				10	1.50 (3.8)	3.27 (3.5)	2.06 (3.1)
				15	1.83 (2.0)	3.71 (2.4)	2.43 (2.1)
				20	2.02 (1.9)	4.14 (2.2)	2.80 (2.0)
				25	2.18 (2.4)	4.48 (2.9)	3.10 (2.5)
				30	2.33 (3.3)	4.83 (3.9)	3.39 (3.4)
				35	2.48 (4.3)	5.17 (5.0)	3.69 (4.5)
				40	2.62 (5.2)	5.48 (6.1)	3.96 (5.4)
				50	2.88 (7.1)	6.07 (8.3)	4.46 (7.4)

INTERPRETATION OF THE FINDINGS & FURTHER RECOMMENDATIONS

Overtly normal cardiac dimensions and function, with no obvious dysfunction or dilation of the left heart. No significant valvular leaks are visualized, and no evidence of pulmonary hypertension. No congenital defects are observed and in the absence of a heart murmur,



PATIENT

Carlos Romero

SPECIES

Canine

BREED

Dachshund

SEX

Male Intact

AGE

5 months

WEIGHT

9lbs

INTERPRETED BY

Maggie Machen Lamy,
DVM, DACVIM
(Cardiology)

IMAGING PERFORMED BY

Cole England, DVM

HOSPITAL NAME

Blue Cross Animal
Clinic

REFERRING VET

Dr. Andrews

INVOICE

47096

DATE

3/4/26

structural disease is considered unlikely. Finally, no pleural effusion is identified; however, small volumes are easy to miss.

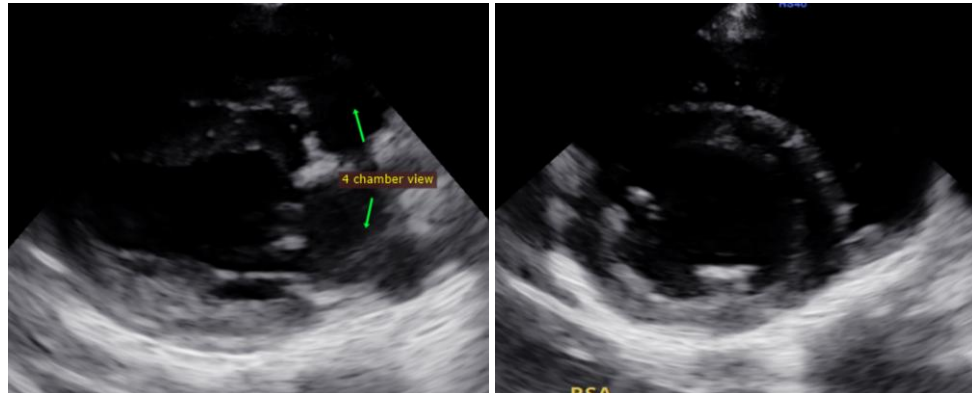
These findings would suggest the radiographic appearance/cough are not due to significant structural disease. Submitting the films for a Radiologist review may be helpful for a thorough pulmonary evaluation.

No medications are indicated and the prognosis is open from a cardiac standpoint.

Monitor for development of a heart murmur, cough, labored breathing, exercise intolerance or collapse episodes.

A recheck echocardiogram is recommended should a significant murmur develop or signs of cardiac compromise be noted in the future.

IMAGES



The information and recommendations provided are based on the images presented by the referring veterinarian. No evaluation can be communicated regarding pathology that was not visible in the image/video clips provided.

Thank you for this referral. This report was generated using transcription software, and minor dictation errors may be present. If the clinical or image interpretation does not parallel your findings or if I can be of any further assistance, please contact me.

Maggie Machen Lamy, DVM

Diplomate of the American College of Veterinary Internal Medicine (Cardiology)

info@sonopath.com